

A horizontal bar at the top of the slide, divided into two sections: a larger teal section on the left and a smaller lime green section on the right.

Eosinophilic oesophagitis

Overview for Multi disciplinary teams

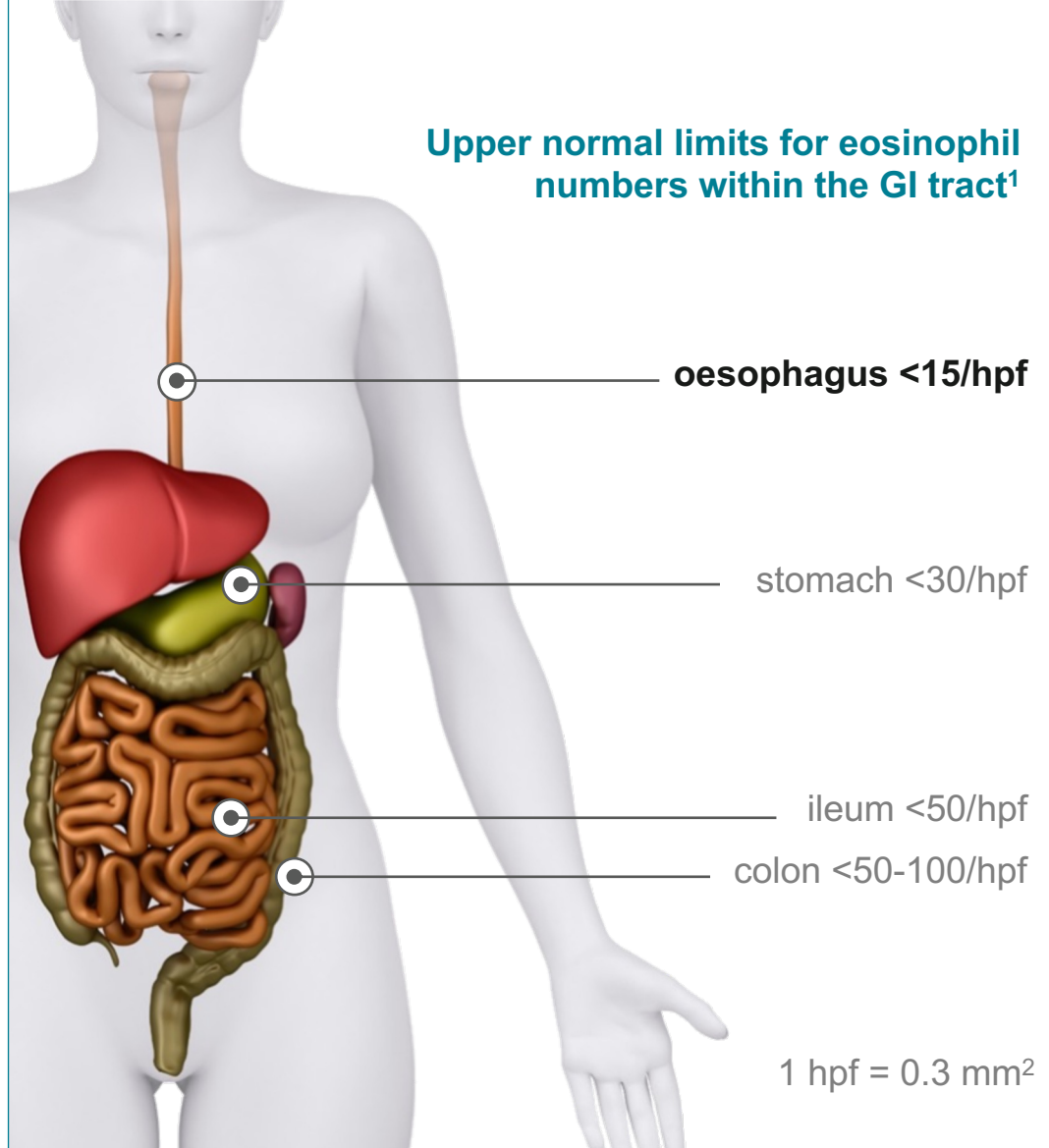
Eosinophil numbers typically increase as you go down the gut¹

1

Eosinophils are typically present throughout the GI tract since it is continuously exposed to foods, environmental allergens, toxins, and pathogens²

2

In healthy individuals, however, the oesophagus is unique in that eosinophils are generally absent²

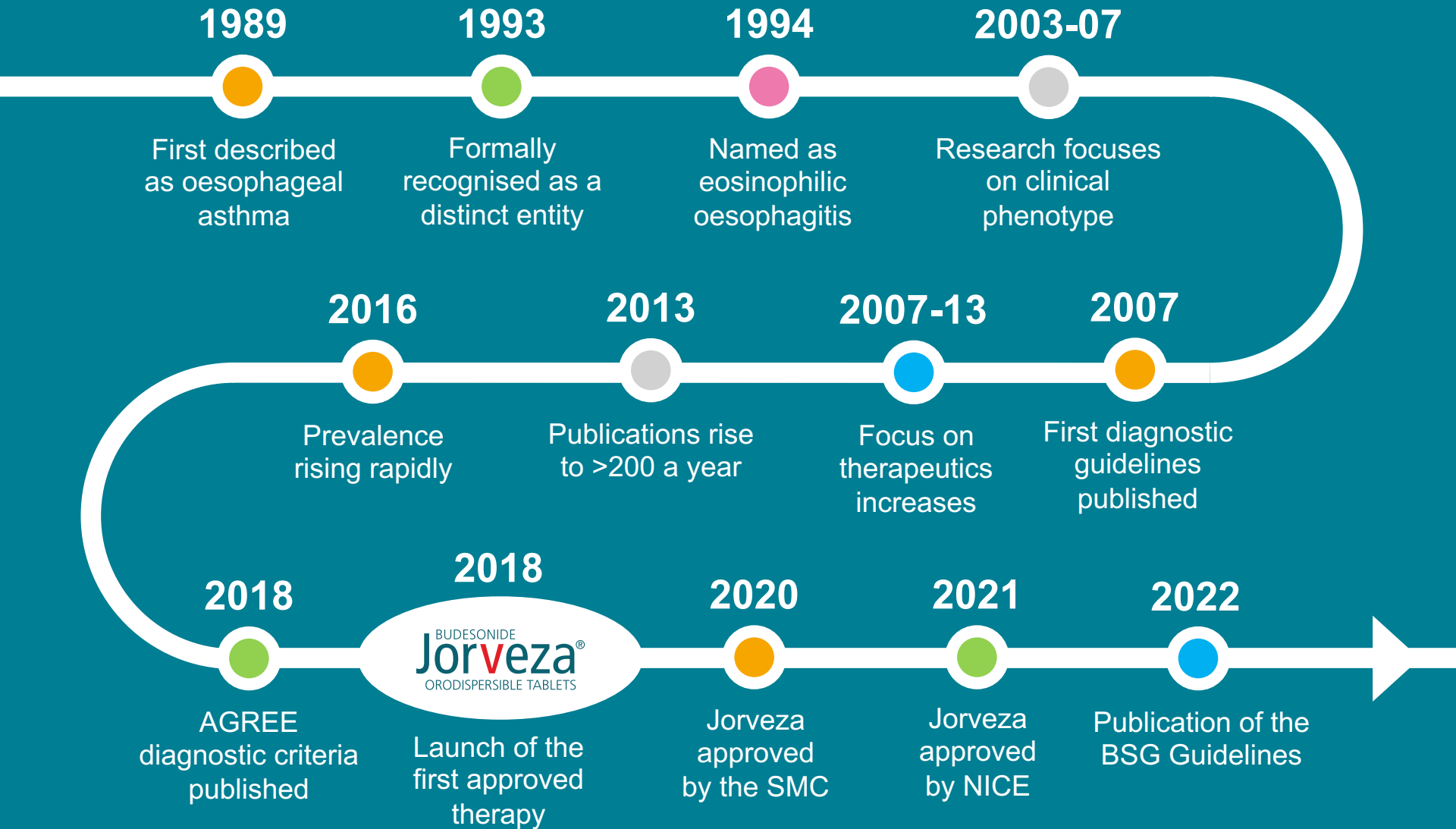


1. Carr S, Watson W. Allergy Asth Immunol ma Clin 2011; 7(Suppl.1): S8.

2. Collins MH. Gastroenterol Clin North Am 2014; 43(2): 257-68.

GI: gastrointestinal
hpf: high-power field

Eosinophilic oesophagitis comes of age



AGREE: A working Group on ppi-REE
BSG: British Society of Gastroenterology
NICE: National Institute for Health and Care Excellence
SMC: Scottish Medicines Consortium

EoE is a chronic, progressive inflammatory disorder in which eosinophils infiltrate the oesophageal epithelium¹

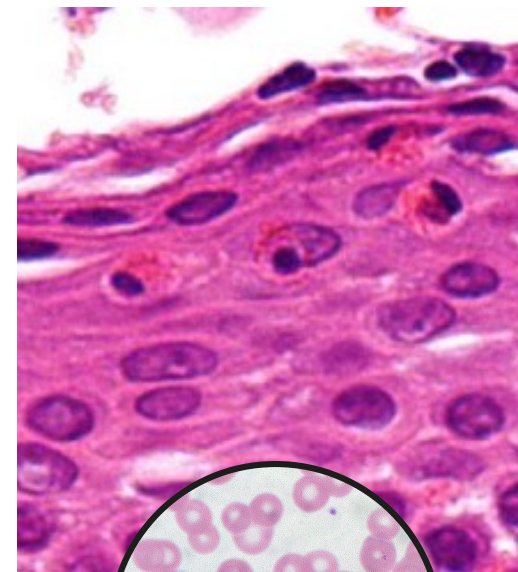
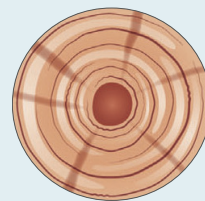
Chronic eosinophilic inflammation leads to:^{2,3}

changes in oesophageal structure:

oesophageal rigidity, fibrostenotic features such as rings and ultimately strictures

changes in oesophageal function:

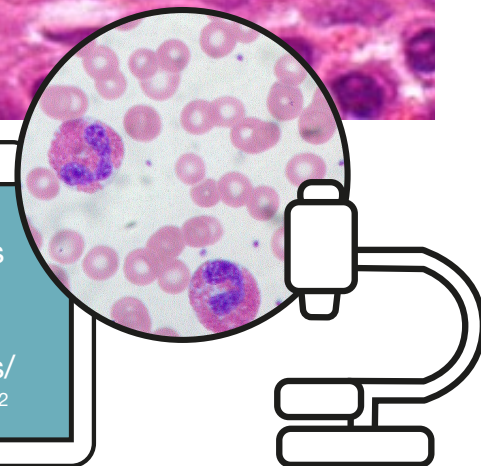
food feels like it is moving slowly/sticking in the chest after swallowing, food impaction



While symptoms such as swallowing difficulties point to EoE, it takes histology to confirm the diagnosis¹

EoE:

≥15 eos
per hpf
or
≥15 eos/
0.3 mm²



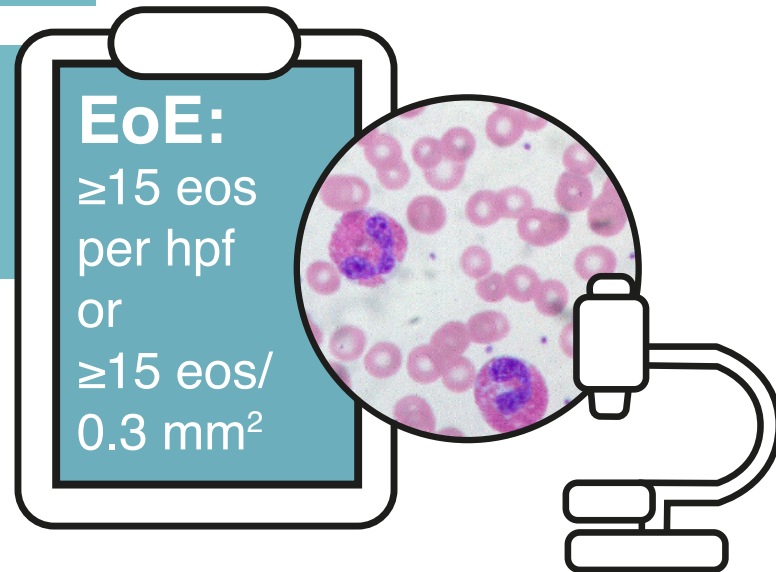
1. Oliva S, Dellon ES. Dig Liver Dis 2021; 53(11): 1476-8.
2. Attwood SE. Br J Hosp Med (Lond) 2019; 80(3): 132-8.
3. Dhar A *et al.* Gut 2022; 71(8): 1459-87.

EoE: eosinophilic oesophagitis
eos: eosinophils
hpf: high-power field

Definition of EoE¹

EoE is an oesophageal disease characterised by symptoms related to oesophageal dysfunction and eosinophil predominant mucosal inflammation

Since most laboratories are moving to digital optical microscopy, the definition of EoE has been expanded in the current guidelines

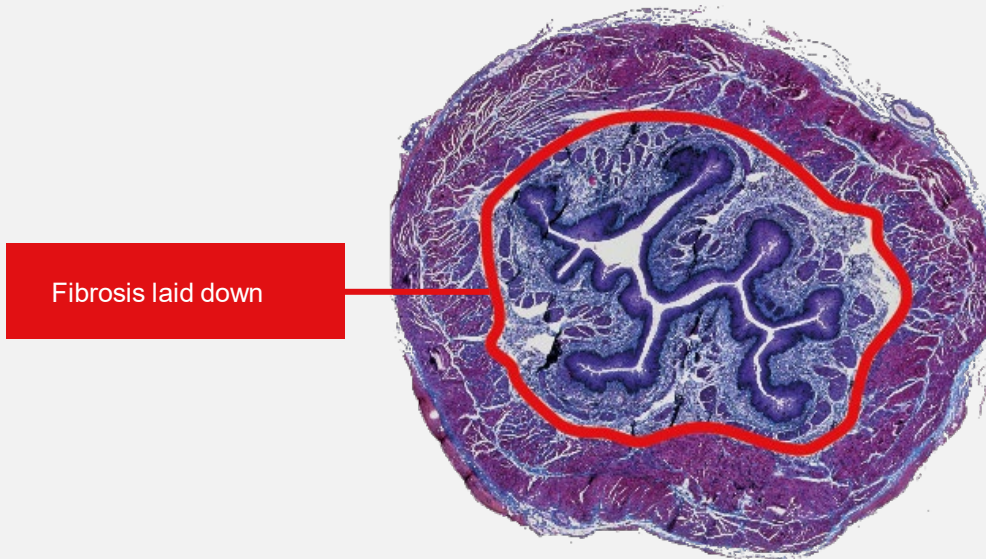


1. Dhar A *et al.* Gut 2022; 71(8): 1459-87.

EoE: eosinophilic oesophagitis
eos: eosinophils
hpf: high-power field

Eosinophilic oesophagitis

- EoE is a progressive inflammatory disorder in which eosinophils infiltrate the oesophageal epithelium¹
- Chronic eosinophilic inflammation leads to changes in oesophageal structure²



- While symptoms such as feeling like food is moving slowly/sticking in the chest after swallowing, or food bolus obstruction, point to EoE, it takes histology to confirm the diagnosis³

Chronic
inflammation



Tissue
changes



Collagen
deposition



Fibrous
remodeling



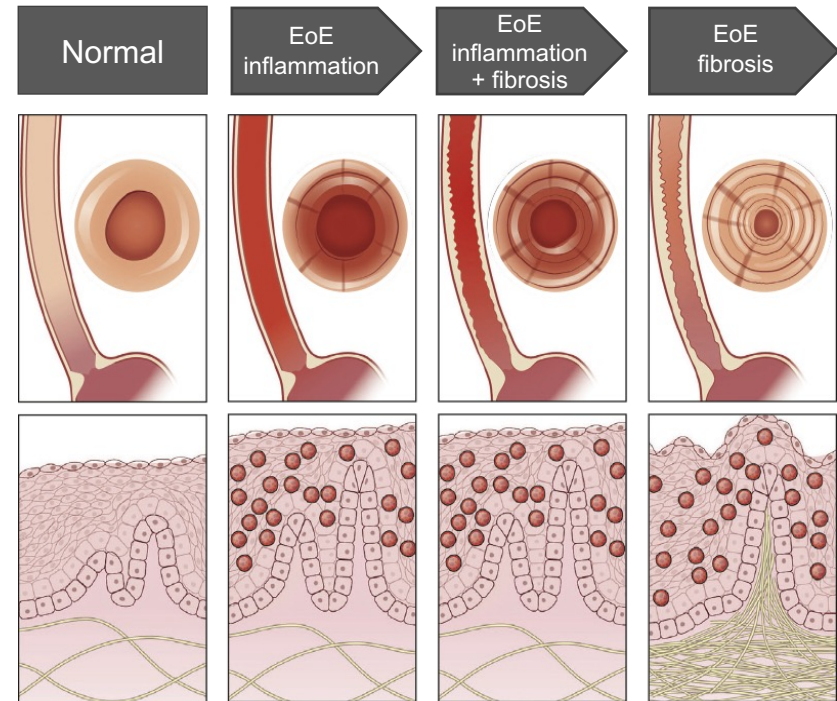
Formation of rings, strictures,
and narrow calibre oesophagus

1. Oliva S, Dellon ES. Dig Liver Dis 2021; 53(11): 1476-8.
2. Lucendo AJ, Molina-Infante J. Expert Rev Clin Immunol 2022; 18(8): 859-72.
3. Attwood SE. Br J Hosp Med (Lond) 2019; 80(3): 132-8.

Natural history of EoE

- EoE is a relatively new disease, so uncertainties remain about its natural history and long-term consequences¹
- Untreated EoE is usually associated with persistent symptoms and inflammation, and it is thought that over time this leads to oesophageal remodelling resulting in stricture formation and functional abnormalities²
- There is some evidence that effective anti-inflammatory treatment may limit progression²
- There is no evidence that EoE is a pre-malignant condition²

Progression of EoE from inflammation to fibrosis*¹

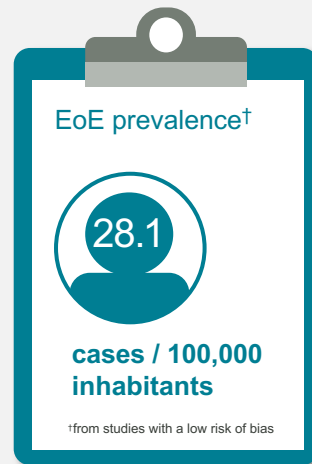
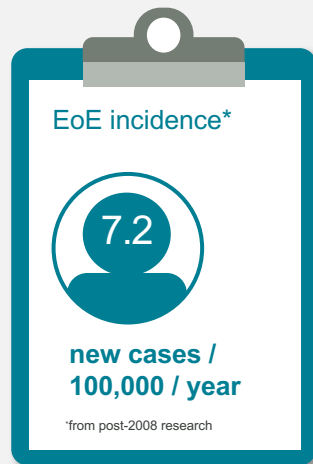
*Reprinted from *Gastroenterology*, vol. 154, Evan S, Dellon *et al.* Epidemiology and Natural History of Eosinophilic Esophagitis, 319-322. © 2018 with permission from Elsevier.

1. Dellon ES, Hirano I. *Gastroenterology* 2018; 154(2): 319-32.
2. Lucendo AJ *et al.* *United Eur Gastroenterol J* 2017; 5(3): 335-58.

Epidemiology of EoE

- A 2016 meta-analysis of 13 population-based studies from North America, Europe and Australia, examined the incidence and prevalence of EoE¹

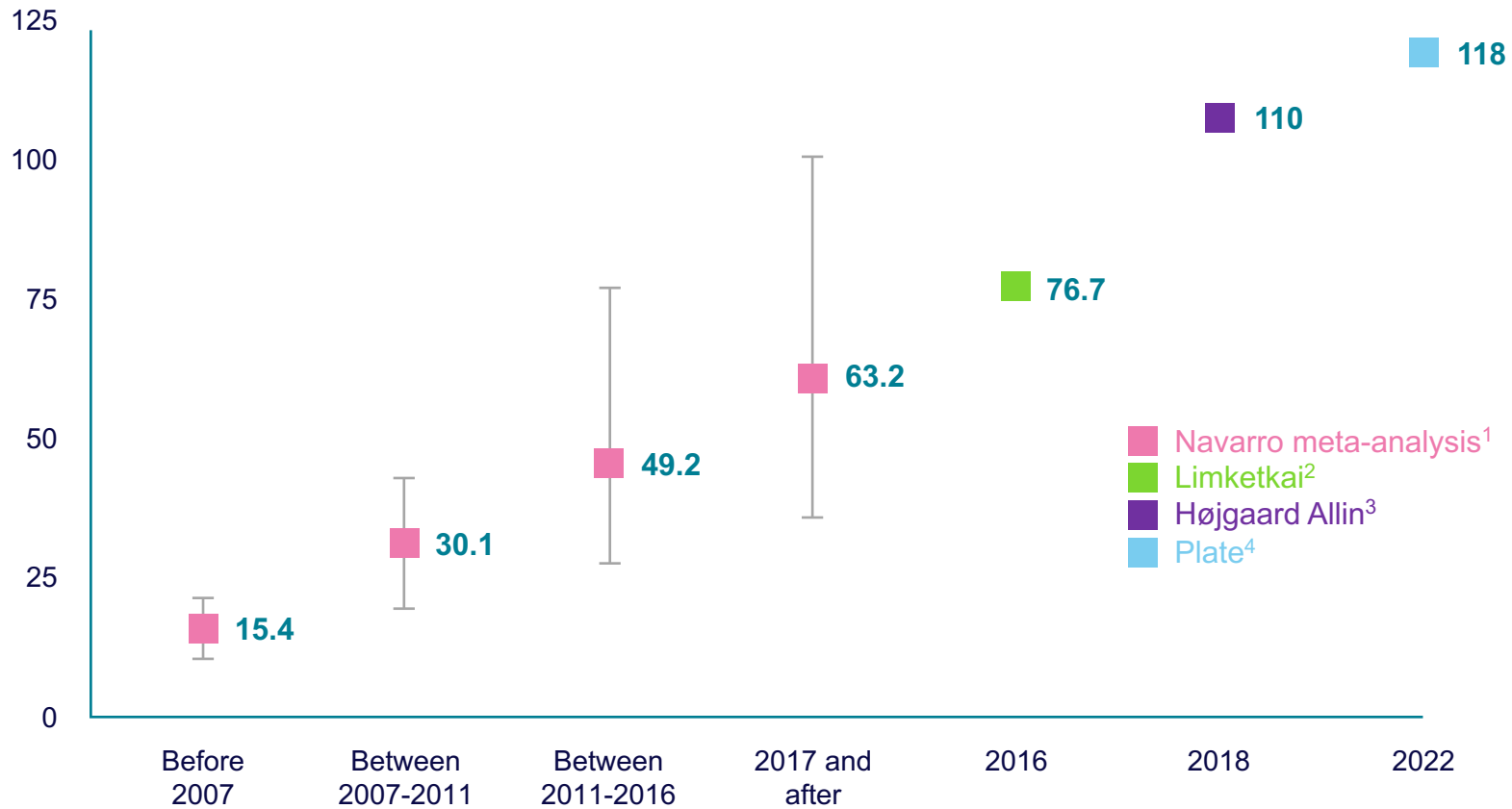

EoE can now be classed as a **highly prevalent disorder**, with the incidence and prevalence rates rising further since this study was published²

1. Arias Á *et al.* *Aliment Pharmacol Ther* 2016; 43(1): 3-15.
2. Limketkai BN *et al.* *Gut* 2019; 68(12): 2152-60.

The progressive rise in the prevalence of EoE

Prevalence / 100,000 of the population¹⁻⁴



1. Navarro P *et al.* Aliment Pharmacol Ther 2019; 49(9): 1116-25.

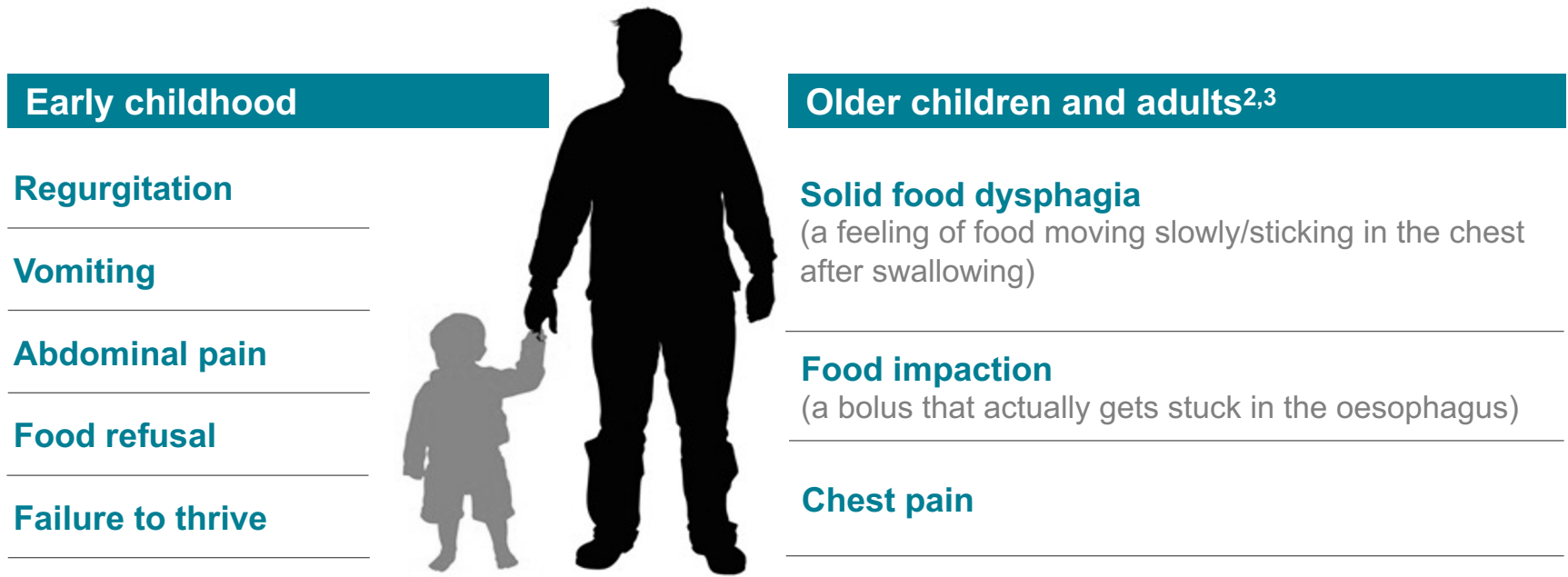
2. Limketkai BN *et al.* Gut 2019; 68(12): 2152-60. (102,048 cases in population 133M)

3. Højgaard Allin K *et al.* United Eur Gastroenterol J 2022; 10(7): 640-50.

4. Plate J *et al.* United Eur Gastroenterol J 2022; 10(Suppl.8): 507.

The most common symptoms of EoE

- The clinical presentation of EoE tends to vary with patient age¹



While young children are more likely to present with non-specific symptoms, they may also present with dysphagia^{1,4}

1. Muir A, Falk GW. JAMA 2021; 326(13): 1310-18.
2. Biedermann L, Straumann A. Nat Rev Gastroenterol Hepatol 2023; 20(2): 101-19.
3. Attwood S, Epstein J. Frontline Gastroenterol 2020; 12(7): 644-9.
4. Fernandez-Becker NQ. Gastroenterol Clin North Am 2021; 50(4): 825-41.

What “dysphagia” means to those with EoE

- A patient with EoE typically has had the condition for many years¹
- As such, they can become used to the sensation of being aware of food travelling down the oesophagus^{1,2}
- They may adapt their eating in order to avoid these sensations, for example, drinking large amounts of water or only eating foods that are known to travel smoothly down the oesophagus¹
- They are prolonged chewers, slow to eat and the last to finish a meal²



1. Dellon ES. Available at: www.med.unc.edu/medicine/news/chairs-corner/podcast/eoe-dellon
Accessed on: 02/06/23.
2. Attwood S. Clin Med 2013; 13(6): s32-s35.

EoE-specific quality of life is correlated with symptoms and disease activity^{1,2}

- In a UK study, patients with EoE had reduced general energy/vitality levels – the condition also had a negative impact on their mental health¹
 - symptoms can be unpleasant, socially embarrassing and restricting^{1,3}
 - choking sensations can cause a sense of panic¹
 - ongoing or repeated courses of treatment may be required¹
 - serious complications requiring endoscopic dilatation may occur¹
 - dietary restrictions can lead to a significantly worse emotional impact³
- Reducing both symptoms and disease activity are important goals for improving QoL in adult patients²
 - having a diagnosis in itself can bring a sense of some relief¹



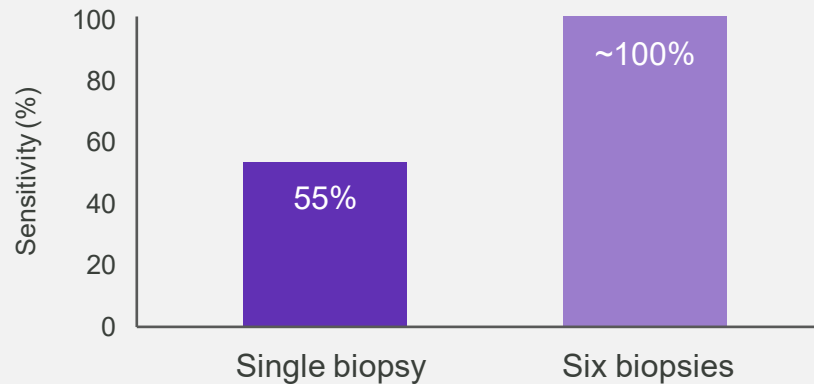
1. Hewett R *et al.* Dis Esophagus 2017; 30(1): 1-7.
2. Safroneeva E *et al.* Aliment Pharmacol Ther 2015; 42(8): 1000-10.
3. Lucendo AL *et al.* United European Gastroenterol J 2018; 6(1): 38-45.

EoE: eosinophilic oesophagitis
QoL: quality of life

At least 6 biopsy samples should be taken to diagnose EoE^{1,2}

- EoE is a patchy disease with considerable variability in the distribution of mucosal eosinophilic infiltration²
 - within the same patient, it is common to see eosinophil counts within both the normal and abnormal range in different segments of the oesophagus

Ability to correctly identify those with EoE³



- It is recommended to take biopsy samples from multiple levels along the length of the oesophagus, ideally targeting areas of visible inflammation, if present²
 - one study found 20% of patients would have been missed if only proximal biopsy samples were taken

1. Dhar A *et al.* Gut 2022; 71(8): 1459-87.
2. Aceves SS *et al.* Gastrointest Endosc 2022; 96(4): 576-92.
3. Beg S *et al.* Gut 2017; 66(11): 1886-99.

Differential diagnosis¹

Patient characteristics	Eosinophilic oesophagitis	Gastro-oesophageal reflux disease	Oesophageal cancer	Dysmotility
Dysphagia	Intermittent / continuous	Unusual	Progressive / continuous	Intermittent with long history
Heartburn	Less common	Characteristic	Previous history	Rare
Chest pain	Can be prominent feature	May occur	Rare	Common
Food impaction	Common	Rare	May occur rarely	Rare / occasional
Vomiting	More common in children	Rare	Rare	No
Regurgitation	Infrequent but secondary to food being stuck	Common but from stomach contents with foul taste	Infrequent but secondary to food being stuck	May occur
History of atopy	Common	No	No	No
Age	Uncommon >60	Any age	>50	Any age
Diagnostic tests				
Endoscopy	Oesophageal rings and vertical furrows may be seen	Distal oesophagitis / distal strictures may be seen	Diagnostic of a tumour	Frequently normal
Biopsy	>15 eos/hpf or >15 eos/0.3 mm ²	<5 eos/hpf or <5 eos/0.3 mm ²	Diagnostic	Normal
Barium swallow	May show strictures or narrow bore oesophagus	May show distal strictures	Can be diagnostic	May show dilation
24-hour pH studies	Normal	Abnormal	N/A	Usually normal
Manometry	Normal or distal obstruction	May be normal or hypomotility	Normal or obstruction	Diagnostic of dysmotility

1. Working Group. Data on file, Dr Falk.

eos: eosinophils
hpf: high-power field

Time to diagnosis of EoE is prolonged

- Despite increasing knowledge of the disease, the length of symptoms before a diagnosis of EoE is made is prolonged¹

Length of symptoms before diagnosis

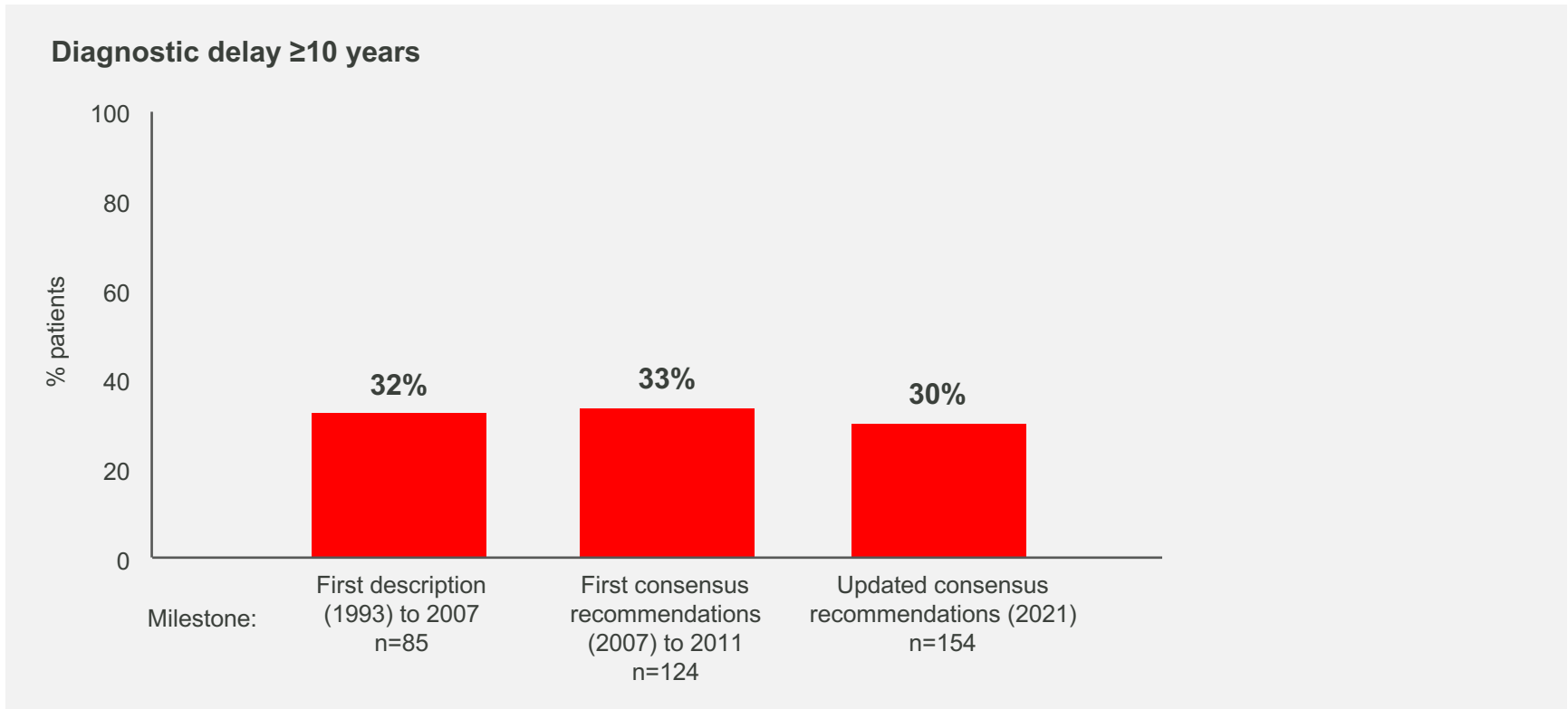


- With each additional year of undiagnosed EoE, the risk of stricture presence increases by 9%²

1. Reed CC *et al.* *Gastroenterology* 2017; 152(5, Suppl.1): S865.
2. Warners MJ *et al.* *Am J Gastroenterol* 2018; 113(6): 836-44.

Substantial efforts are warranted to increase awareness for EoE¹

- A persistently stable fraction of roughly one-third of all patients wait over 10 years for a diagnosis¹



1. Murray FR *et al.* Am J Gastroenterol 2022; 117: 1772-9.

Distinguishing GORD from EoE

- While it is important to distinguish between EoE and GORD, this can be challenging as many of their clinical and histological features overlap¹⁻³

Factors	EoE	GORD
Dominant symptom	Dysphagia	Heartburn Regurgitation
Food impaction	Common	Uncommon
Gender	Male predominance	Male = Female
Age	Children, young adults	Middle age
Endoscopic findings	Oedema, rings, exudates furrows, strictures, crepe-paper oesophagus, narrow calibre oesophagus	Erosions, ulcers, Barrett metaplasia, hiatal hernia, strictures
	Normal findings on endoscopy – minority	Normal findings on endoscopy – majority
Histology	≥15 eos/hpf	<7 eos/hpf
Distribution of eosinophilia	Diffuse more suggestive of EoE	Distal more suggestive of GORD
Additional histological features (BZH, EA, ESL, DIS, SEA, DEC, LPF)	More commonly found	Less commonly found
Positive intercellular IgG4 stain	~75%	<10%

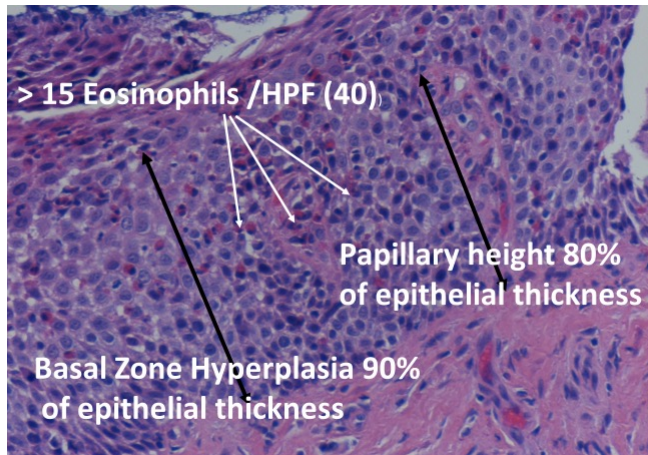
1. Wong S *et al.* JGH Open 2020; 4(5): 851-5.
2. Kia L, Hirano K. Nat Rev Gastroenterol Hepatol 2015; 12(7): 379-86.
3. Wong S *et al.* World J Gastrointest Pathophysiol 2018; 9(3): 63-72.

BZH: basal zone hyperplasia
 DEC: dyskeratotic epithelial cells
 DIS: dilated intercellular spaces
 EA: eosinophil abscess
 EoE: eosinophilic oesophagitis
 eos/hpf: eosinophils/high power field

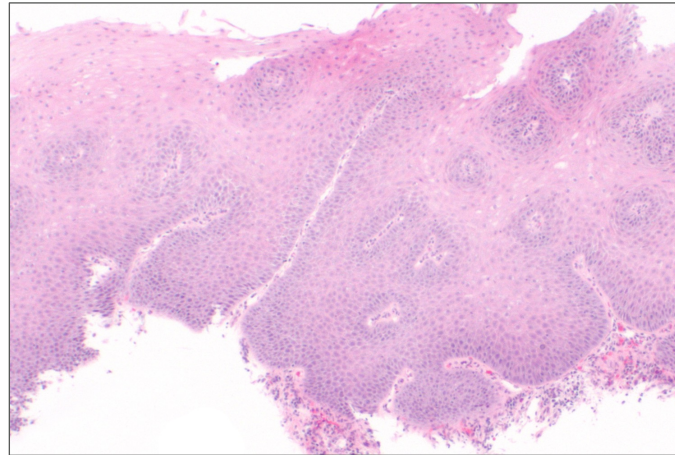
ESL: eosinophil surface layering
 GORD: gastro-oesophageal reflux disease
 LPF: lamina propria fibrosis
 SEA: surface epithelial alteration

EoE and GORD have differences in their histological presentations¹

EoE



GORD



1. Wong S *et al.* World J Gastrointest Pathophysiol 2018; 9(3): 63-72.

EoE: eosinophilic oesophagitis
GORD: gastro-oesophageal reflux disease
hpf: high power field

Diagnosing EoE – a UK DGH experience¹

- Study investigating management of patients presenting with symptoms conducive with EoE to two district general hospitals over a year

Patients presenting with dysphagia/FBO undergoing gastroscopy (n=442)	
Female	58%
Average age	65
% of patients biopsied	50%
% of patients biopsied suspected of having EoE	40%
% of biopsies positive for EoE	8%

“EoE detection is likely to improve further if all patients with symptoms conducive with EoE (e.g. solid food dysphagia) routinely trigger an EoE biopsy protocol”

1. Osuha H *et al.* Gut 2015; 64(Suppl.1): A21.

DGH: district general hospital
EoE: eosinophilic oesophagitis
FBO: food bolus obstruction

Predicting EoE in dysphagic adults with a normal endoscopy¹

- Study investigating clinical risk factors predictive for EoE that could guide the endoscopist for when to take biopsies, thereby saving time and money

Patients presenting with dysphagia/FBO and a new diagnosis of EoE (eosinophils >15/hpf) (n=127)		Patients presenting with dysphagia/FBO but no evidence of EoE on biopsies (n=127)		“In patients presenting with dysphagia or FBO and a normal endoscopy, utilising a simple bedside tool comprising of age (<46 years) and male sex can reliably predict the presence of EoE”
Male	75%	Male	46%	
Average age	39	Average age	60	

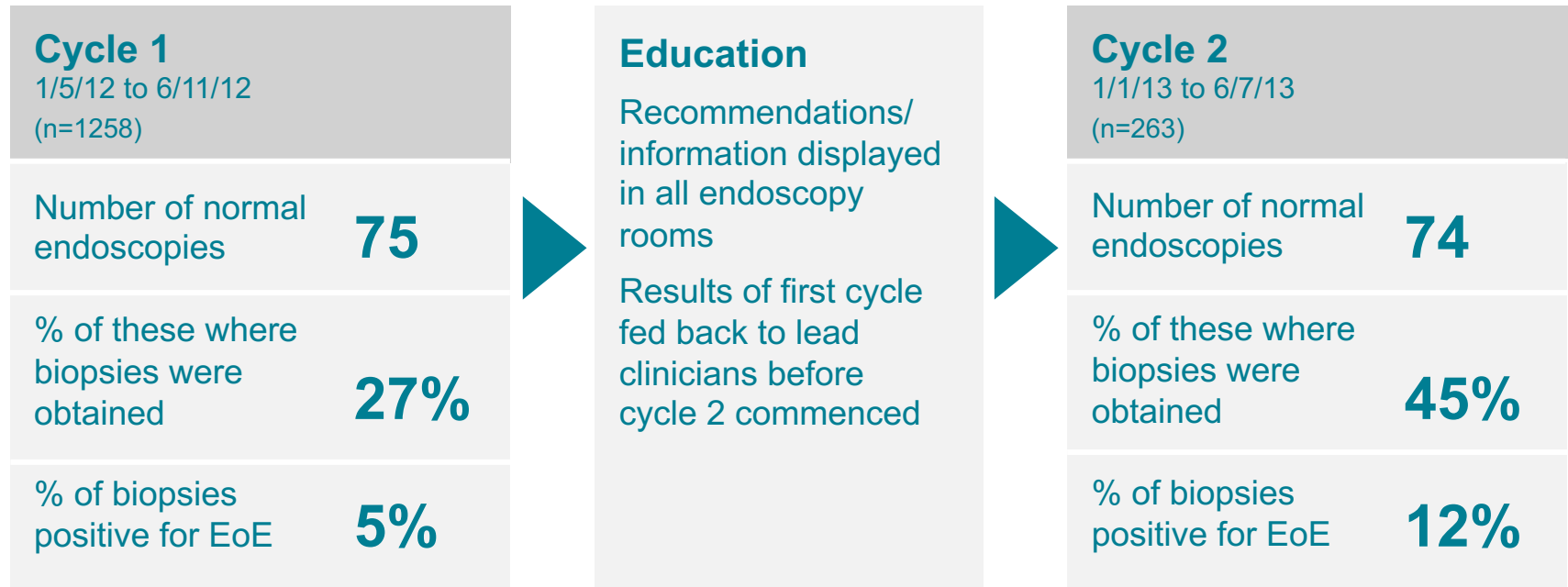
- A multivariate logistic regression analysis identified age ($p < 0.001$) and sex ($p < 0.001$) as the strongest predictors of EoE
 - the optimal cut-off for age was 46 years (sensitivity: 86%, specificity: 69%)

1. Ibraheim H *et al.* Gut 2017; 66(Suppl.2): A18-19.

EoE: eosinophilic oesophagitis
FBO: food bolus obstruction
hpf: high-power field

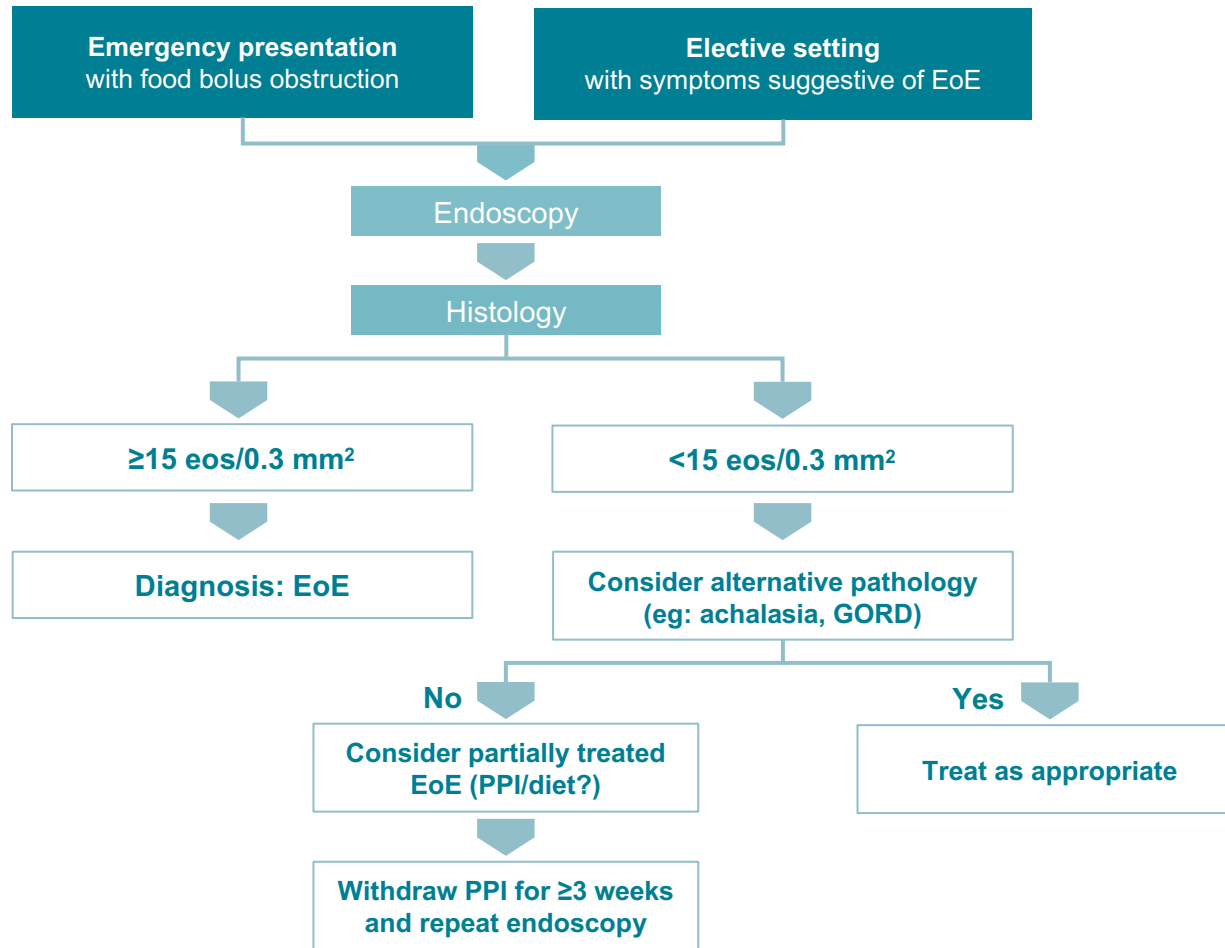
EoE diagnostic rates can be improved by education¹

- Study investigating the adherence to guidelines recommending obtaining biopsies in patients with dysphagia who have normal endoscopies



1. Davies A *et al.* Gut 2014; 63(Suppl.1): A46.

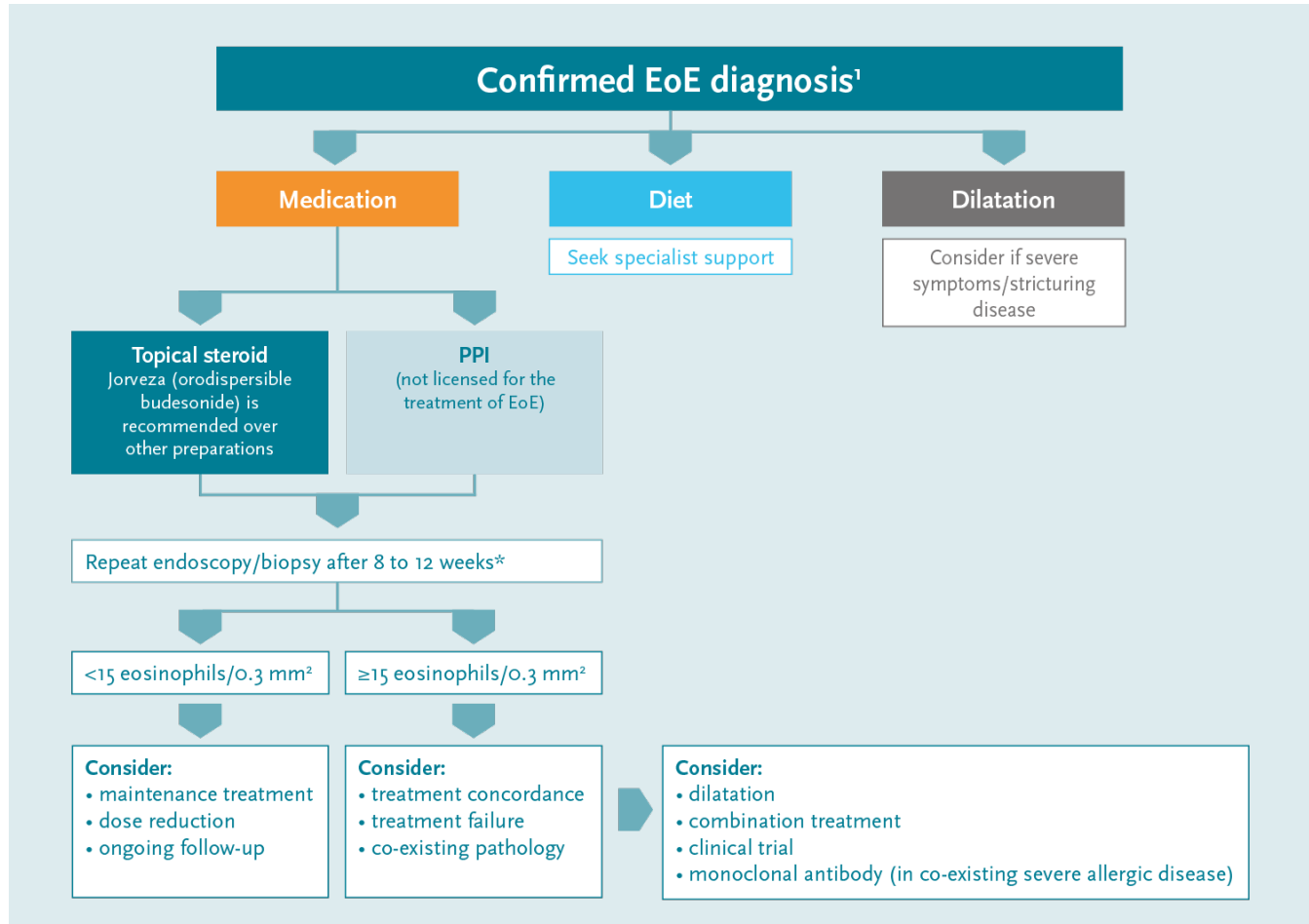
Diagnosis¹



1. Dhar A *et al.* Gut 2022; 71(8): 1459-87.

EoE: eosinophilic oesophagitis
eos: eosinophils
GORD: gastro-oesophageal reflux disease
PPI: proton pump inhibitor

Management¹

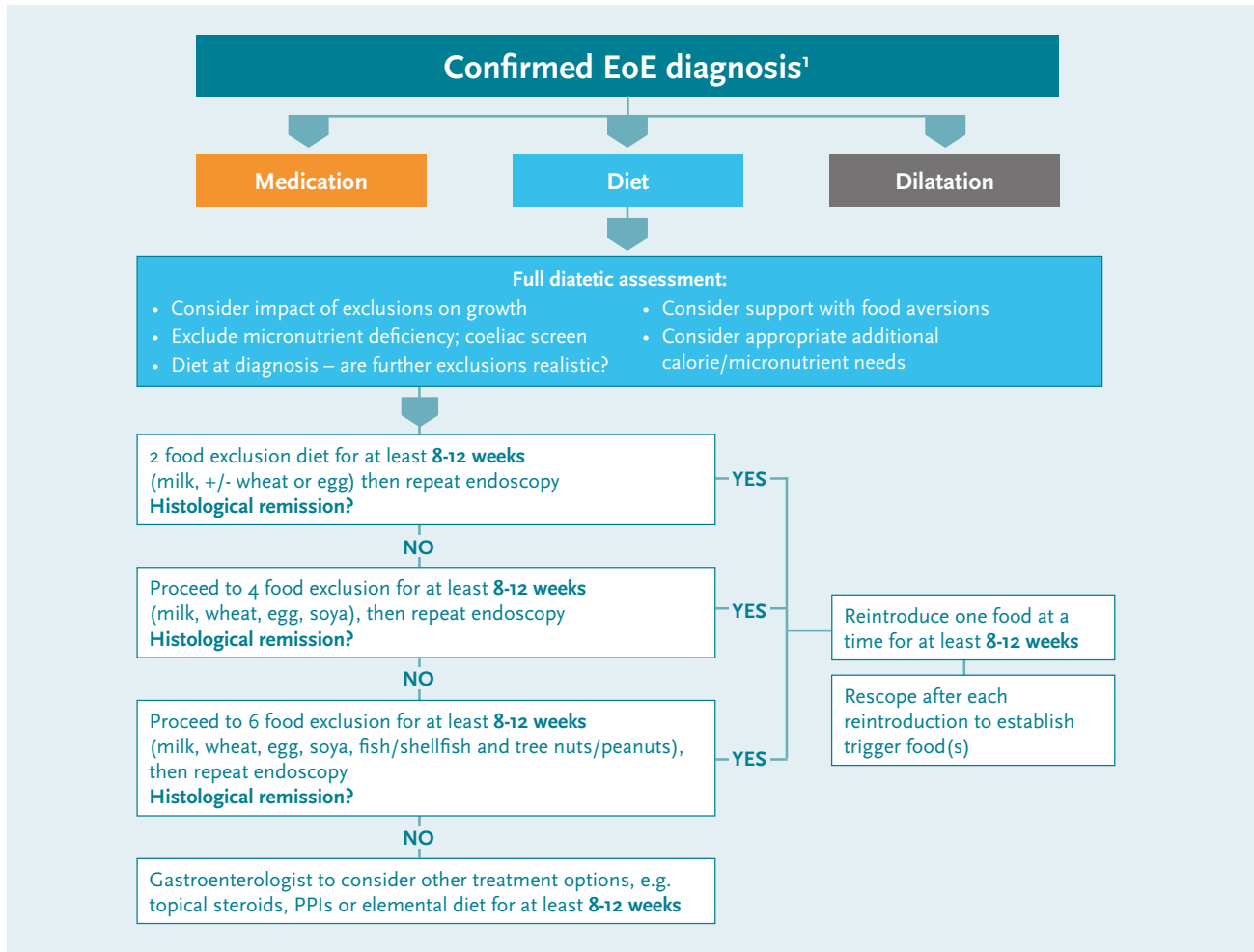


*Data from a phase III induction study suggest prolongation of Jorveza therapy to 12 weeks is beneficial to bring more patients into clinico-histologic remission²

1. Dhar A *et al.* Gut 2022; 71(8): 1459-87.
2. Lucendo AJ *et al.* Gastroenterology 2019; 157: 74-86.

EoE: eosinophilic oesophagitis
PPI: proton pump inhibitor

Management: diet¹



*Data from a phase III induction study suggest prolongation of Jorveza therapy to 12 weeks is beneficial to bring more patients into clinico-histologic remission²

1. Dhar A *et al.* Gut 2022; 71(8): 1459-87.


EoE: eosinophilic oesophagitis
PPI: proton pump inhibitor

Drug treatment of EoE: corticosteroids

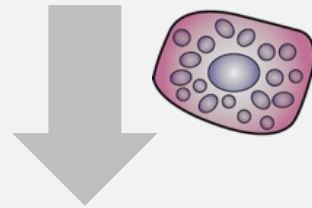
- As seen in a number of other allergic diseases, eosinophilia is relatively responsive to the administration of corticosteroids¹
- Topical corticosteroids have also been shown to reduce oesophageal remodelling²

Impact of budesonide in the oesophageal mucosa on factors accompanying inflammation and lamina propria fibrosis³

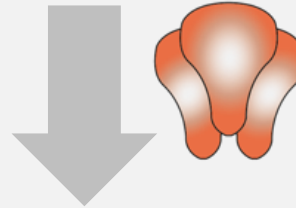
Eosinophils



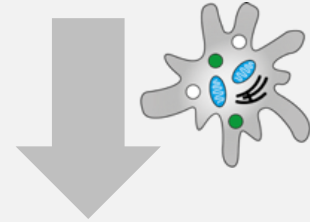
Mast cells



Tumour necrosis factor- α



Epithelial cell apoptosis

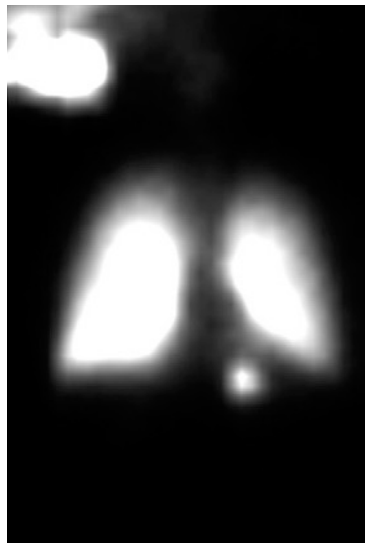


- While trials have used different agents, delivery systems, and dosages, at least a partial symptomatic response is seen in about 60-75% of adults; a similar proportion achieve a complete histologic response⁴
- Use of systemic steroids is not recommended because of adverse effects¹

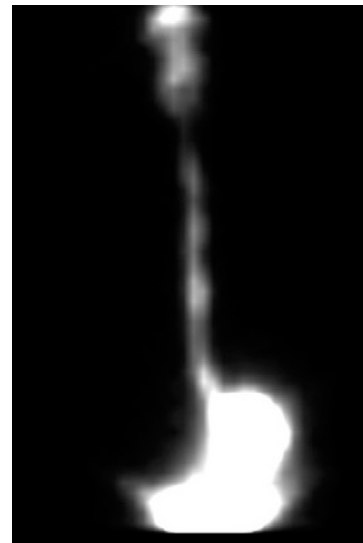1. Schroeder S *et al.* Expert Rev Clin Immunol 2010; 6(6): 929-37.
2. Straumann A, Katzka DA. Gastroenterology 2018; 154(2): 346-59.
3. Alexander JA, Katke DA. Gastroenterol Hepatol 2011; 7(1): 59-61.
4. Alexander JA. Gastroenterol Hepatol 2014; 10(5): 327-9.

Off-label corticosteroids are not optimised for oesophageal delivery¹

- Asthma steroid preparations have been swallowed rather than inhaled to coat the oesophagus, but are suboptimal for use in EoE¹
- Undesired lung deposition can result from medication administered into the mouth using metered-dose inhalers^{1,2}
- While there is greater oesophageal deposition with topical viscous steroids, variable drug concentrations are possible when patients mix aqueous forms into slurries^{1,2}



Nebulised
swallowed
budesonide²



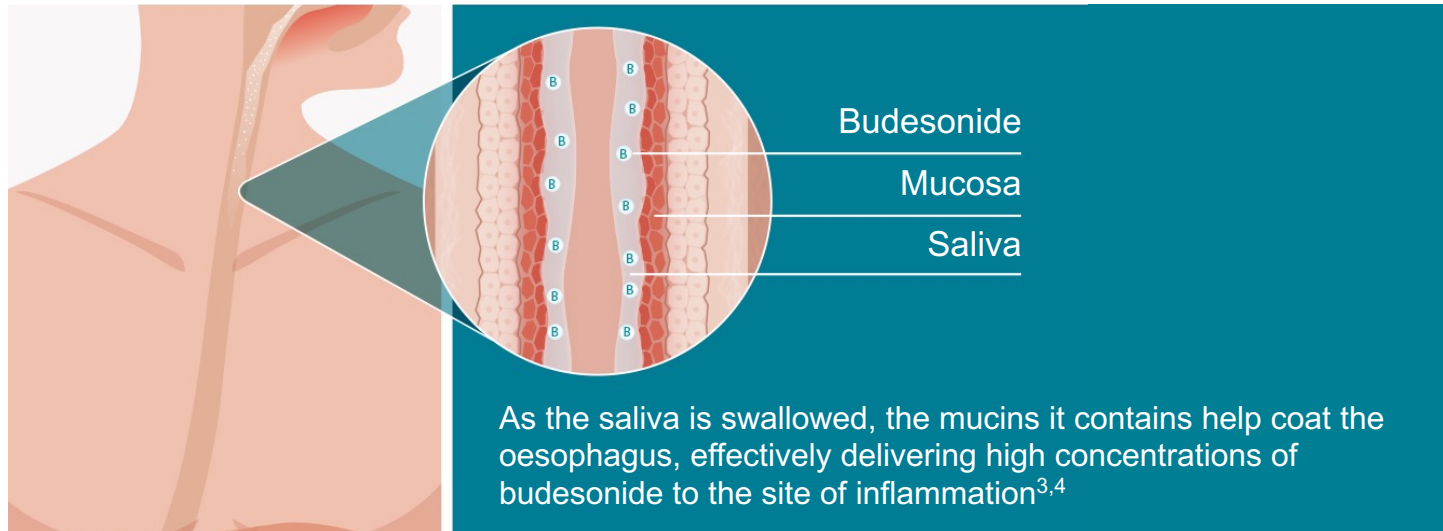
Oral viscous
budesonide²

Reprinted from *Gastroenterology*, vol. 143, issue 2, Evan S. Dellon et al, Viscous Topical Is More Effective Than Nebulized Steroid Therapy for Patients With Eosinophilic Esophagitis, 321-324, © 2012 with permission from Elsevier.

1. Dellon ES *et al.* *Gastroenterology* 2017; 152(4): 776-86.
2. Dellon ES *et al.* *Gastroenterology* 2012; 143(2): 321-4.

Orodispersible budesonide (Jorveza) is the first licensed medical treatment for EoE¹

- Jorveza is an immediate release budesonide tablet specifically designed to treat EoE²
- The Jorveza tablet is placed on the tongue where it starts to effervesce, stimulating the production of saliva³

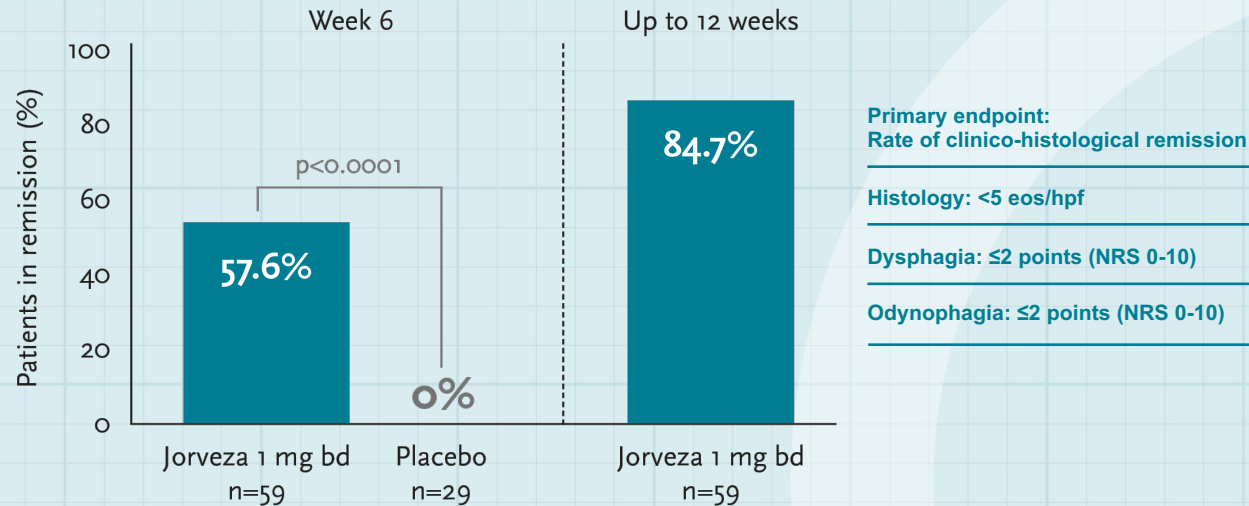


The BSG recommend Jorveza - the only medicine with European regulatory approval for EoE - over other steroid formulations for both the induction and maintenance of remission in adults⁵

1. Jorveza Summary of Product Characteristics.
2. Lucendo AJ *et al.* *Gastroenterology* 2019; 157(1): 74-86.
3. Data on file, Dr Falk.
4. Dodds MWJ *et al.* *J Dentistry* 2005; 33(3): 223-33.
5. Dhar A *et al.* *Gut* 2022; 71(8): 1459-87.

Jorveza 1 mg bd rapidly improves EoE symptoms and reduces disease activity¹

Clinical-histological remission with orodispersible Jorveza 1 mg bd induction therapy¹



Adapted from Lucendo¹



Prolongation of Jorveza therapy to 12 weeks is beneficial to bring more patients into clinico-histologic remission¹

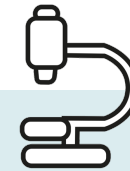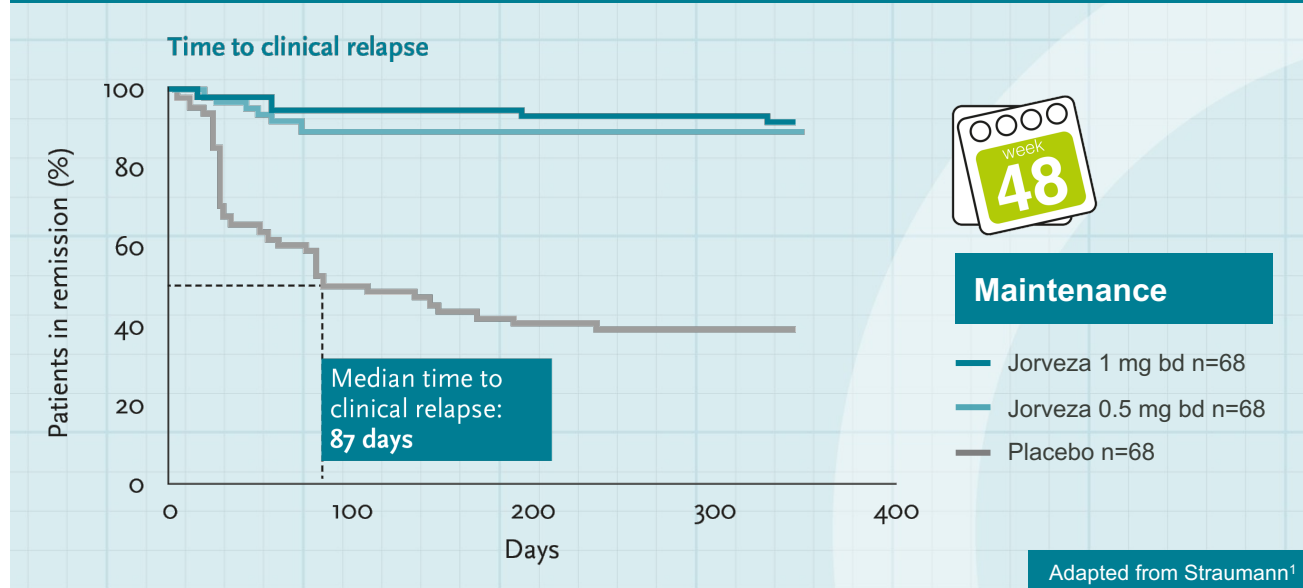
1. Lucendo AJ *et al.* Gastroenterology 2019; 157: 74-86.

EoE: eosinophilic oesophagitis
eos: eosinophils
hpf: high-power field
NRS: numerical rating scale

Jorveza is highly effective at maintaining remission in patients with EoE¹

Clinical remission

While half of placebo patients had relapsed within 3 months, over 90% of Jorveza patients were still in remission at week 48¹



Histological remission
90% of placebo patients had experienced a histological relapse versus only 12% of Jorveza patients at week 48¹

20
BSG GUIDELINES
22

“ This study reported greater efficacy than all previous studies on maintenance therapy using swallowed inhaled topical steroids² ”

1. Straumann A *et al.* *Gastroenterology* 2020; 159(5): 1672-85.
2. Dhar A *et al.* *Gut* 2022; 71(8): 1459-87.

Drug treatment of EoE: PPIs

Please note, while PPIs are a very commonly prescribed class of drugs in the UK, when it comes to EoE, they are not licensed for use^{1,2}

- The proposed mechanism(s) through which PPIs function to reduce eosinophilia in EoE have been the subject of much debate and include:³

PPI induced gastric acid-suppression leading to a restoration of oesophageal barrier function³

Since oesophageal exposure to acid causes more pain in patients with EoE than in healthy individuals, acid blockade may also reduce the symptoms of EoE⁴

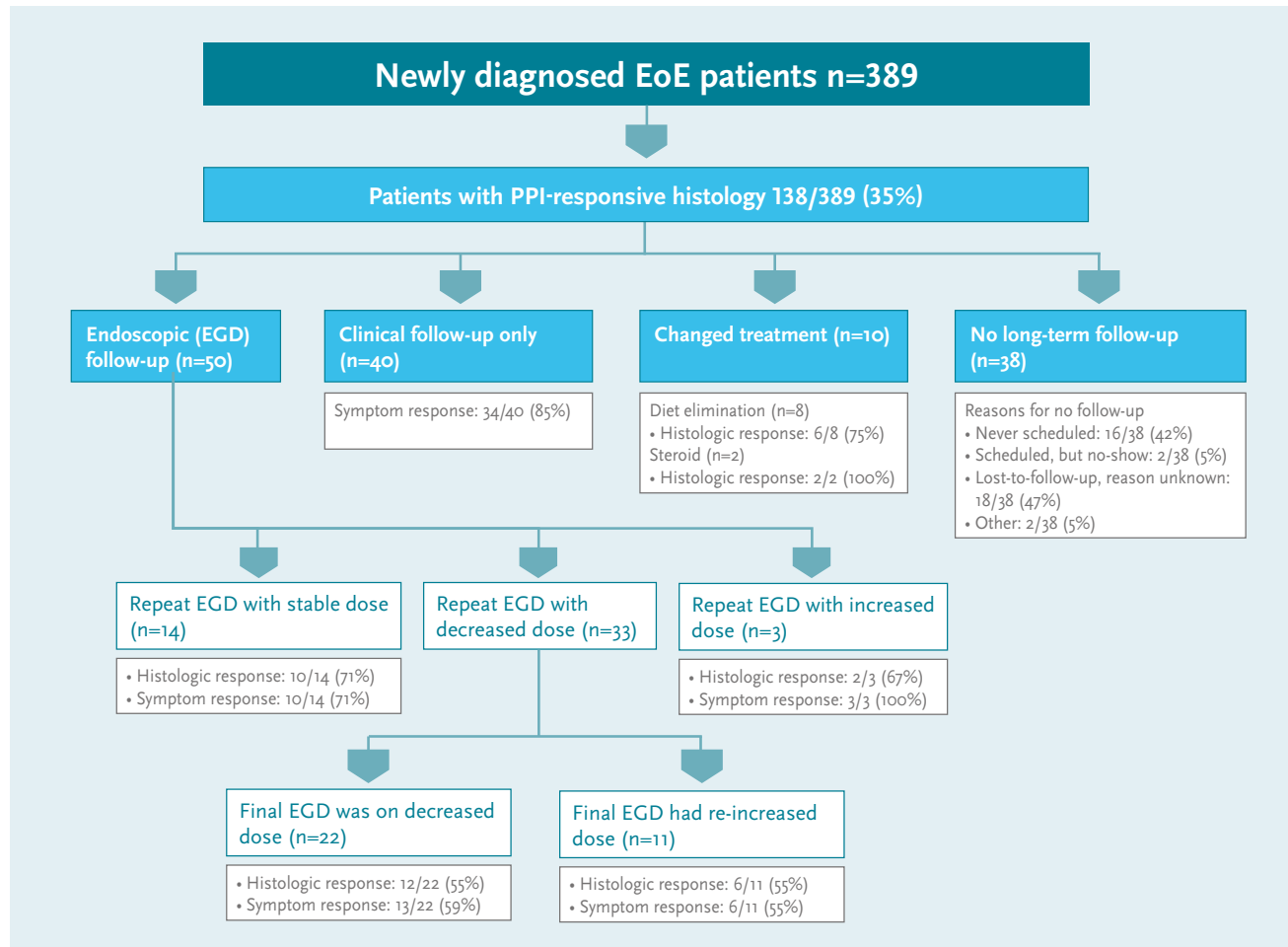
PPI mediated anti-inflammatory effects unrelated to gastric acid suppression³

For example, PPIs decrease IL-4-stimulated eotaxin-3 expression and so may have an anti-eosinophil effect⁵

1. Audi S *et al.* Br J Clin Pharmacol 2018; 84(11): 2562-71.
2. Dhar A *et al.* Gut 2022; 71(8): 1459-87.
3. Franciosi JP *et al.* J Asthma Allergy 2022; 15: 281-302.
4. Straumann A, Katzka DA. Gastroenterology 2018; 154(2): 346-59.
5. Zhang X *et al.* PLoS One 2012; 7(11): e50037.

EoE: eosinophilic oesophagitis
PPI: proton pump inhibitor

Efficacy of PPIs in the treatment of EoE¹



Retrospective cohort study of patients at a US university hospital¹

1. Thakkar KP *et al.* Dig Liver Dis 2022; 54(9): 1179-85.

EGD: esophagogastroduodenoscopy
 EoE: eosinophilic oesophagitis
 PPI: proton pump inhibitor

Long-term safety of PPI treatment

- While the short-term use of PPIs is considered generally safe, their long-term safety profile is controversial^{1,2}
- Side effects associated with PPI use are also known to be dose dependent²
- The daily dose used for induction therapy – for example, omeprazole 20 mg bd - is generally double the standard PPI dose^{3,4}
- Use of quadruple doses has also been reported⁴



“ As PPI therapy in EoE may potentially be long-term and high dose, consideration of adverse events is important for prescribers and patients² ”

1. He Q *et al.* *Am J Gastroenterol* 2021; 116(11): 2286-91.
2. Franciosi JP *et al.* *J Asthma Allergy* 2022; 15: 281–302.
3. Dhar A *et al.* *Gut* 2022; 71(8): 1459-87.
4. Laserna-Mendieta EJ *et al.* *Aliment Pharmacol Ther* 2020; 52(5):798-807.

EoE: eosinophilic oesophagitis
PPI: proton pump inhibitor

Dietary approaches for the treatment of EoE

- Given the link between EoE and food allergens, dietary avoidance is a logical treatment option¹
- The three approaches:¹⁻⁵

1. Elemental diet

- amino acid-based allergen-free formula, followed by slow reintroduction of foods
- the most effective but also the most strict diet
- the need to forgo all food has significant social limitations
- patients often have difficulties with adherence

2. Testing-directed elimination diet


- elimination of food groups based on allergy testing
- avoiding only 1-2 foods based on tests is appealing to patients
- can be time-consuming, expensive, and limited by false-positive rates
- overall poor efficacy and the least favoured of the 3 dietary regimens

3. Empiric elimination diet (2-4-6 food elimination diet)

- avoidance of the food types that are most commonly associated with allergy
- milk and wheat are most frequently implicated; followed by eggs and soy, then nuts and seafood
- entails stepwise reintroduction of foods with multiple follow-up endoscopies
- probably the preferred diet despite the cumbersome process

1. Goyal A, Cheng E. *World J Gastrointest Pharmacol Ther* 2016; 7(1): 21-32.
2. Lipowska AM I *et al.* *EMJ Allergy Immunol* 2016; 1(1): 74-81.
3. Yaxley JP, Chakravarty B. *Aust Fam Physician* 2015; 44(10): 723-7.
4. Eluri S, Dellon ES. *Clin Gastroenterol Hepatol* 2017; 15(11): 1668-70.
5. Dhar A *et al.* *Gut* 2022; 71(8): 1459-87.

Dietary therapy for EoE




Multiple endoscopies (>7) are required to identify the causative foods¹

Patients need intensive dietetic support to prevent vitamin and nutrient deficiencies²

Significant modification of lifestyle is to the detriment of quality of life^{3,4}

The initial success rate of 2-4-6 diet was only 43%⁵



Few adults have the perseverance required⁶

Specialised diets causes psychosocial difficulties in children and adolescents⁷

1. Dhar A *et al.* Gut 2022; 71(8): 1459-87.
2. Goyal A, Cheng E. World J Gastrointest Pharmacol Ther 2016; 7(1): 21-32.
3. Lucendo AJ *et al.* Aliment Pharmacol Ther 2017; 46(4): 401-9.
4. Lucendo AJ *et al.* United European Gastroenterol J 2015; 6(1): 38-45.
5. Molina-Infante J *et al.* J Allergy Clin Immunol 2018; 141(4): 1365-72.
6. Gonsalves N *et al.* Gastroenterology 2012; 142: 1451-5.
7. Case C *et al.* J Pediatr Gastroenterol Nutr 2017; 65(3): 281-4.

The new BSG guidelines recommend maintenance therapy for EoE¹

Clinical and histological relapse is high after withdrawal of topical steroid treatment and, following clinical review, maintenance treatment should be recommended¹

Grade of evidence: Moderate

Level of recommendation: Strong



The BSG recommend Jorveza (orodispersible budesonide) – the only medicine with European regulatory approval for EoE – over other steroid formulations for both the induction and maintenance of remission in adults¹

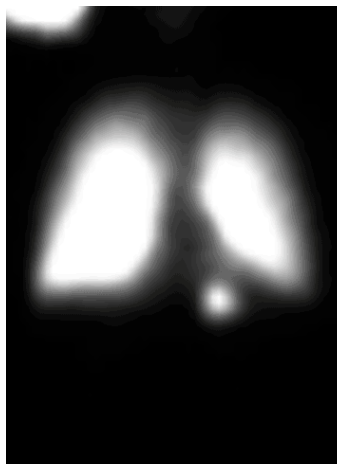
1. Dhar A *et al.* Gut 2022; 71(8): 1459-87.

The most effective specific therapy for EoE is topical steroid treatment¹

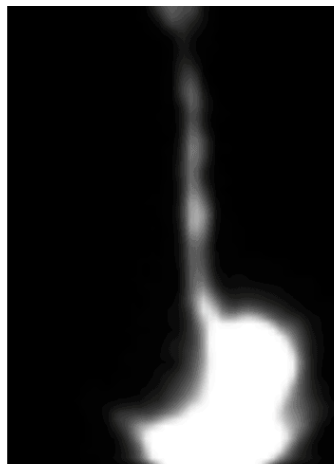- Topical steroids are, however, only as effective as their ability to effectively uniformly coat the oesophageal mucosa²

Off-label formulations do not provide a standardised way of getting topical steroids to the surface of the oesophagus^{3,4}

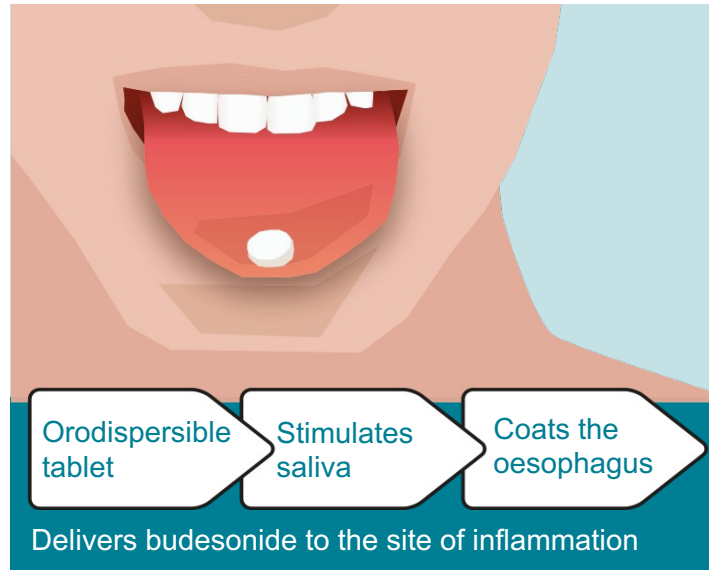
Jorveza is the only topical steroid specifically designed to target the oesophagus in patients with EoE⁵



Nebulised and swallowed steroid



Oral steroid slurry



Reprinted from *Gastroenterology*, vol. 143, issue 2, Evan S. Dellon *et al*, Viscous Topical Is More Effective Than Nebulized Steroid Therapy for Patients With Eosinophilic Esophagitis, 321-324, © 2012 with permission from Elsevier.


1. Attwood S, Epstein J. *Frontline Gastroenterol* 2020; 12(7): 1644-9.
2. Katzka DA *et al*. *Gastroenterology* 2020; 159(3): 813-15.
3. Dellon ES *et al*. *Gastroenterology* 2017; 152(4): 776-86.
4. Dellon ES *et al*. *Gastroenterology* 2012; 143(2): 321-4.
5. Miehlke S *et al*. *Therap Adv Gastroenterol* 2020; 13: 1756284820927282.

EoE: eosinophilic oesophagitis

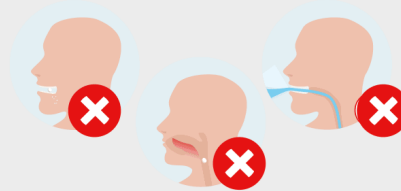
Jorveza instructions for use

Jorveza is placed on the tip of the tongue, then gently pressed against the roof of the mouth while it dissolves.

It should take about 2 minutes for the Jorveza tablet to dissolve completely.



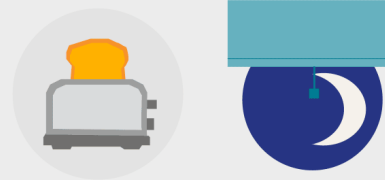
Jorveza should not be chewed, or swallowed undissolved, or taken with liquid.



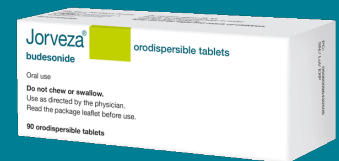It's very important that patients give Jorveza time to work. So, at the very least, they should leave 30 minutes before eating, drinking, cleaning teeth or chewing gum.



It may help if patients take Jorveza after they have had breakfast and brushed their teeth in the morning and very last thing at night, just as they go to bed. That way Jorveza will stay in contact with the oesophagus for as long as possible.

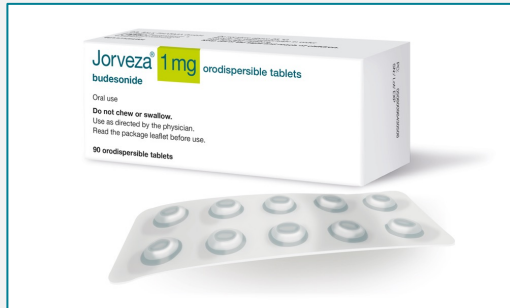

See an animation
on how to take
Jorveza here



Jorveza recommended dosage

Induction of remission¹

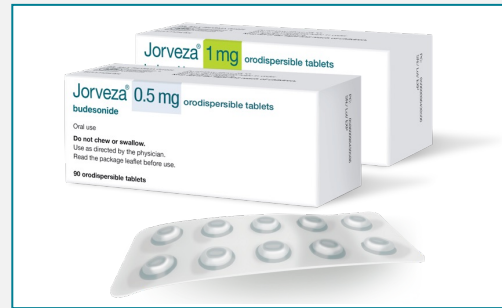

1 mg bd

6 to 12 weeks*

*Prolongation of therapy to 12 weeks is beneficial to bring more patients into remission²

Maintenance of remission¹



0.5 mg or 1 mg bd*

Duration determined by the treating physician

*1 mg bd is recommended for patients with long-standing disease history and/or high extent of oesophageal inflammation in the acute disease state

1. Jorveza Summary of Product Characteristics.
2. Lucendo AJ *et al.* Gastroenterology 2019; 157(1): 74-86.

Prescribing information

Please click on the following link for the prescribing information:

<https://www.dralfk.co.uk/jorveza-1mg-oro-dipsersible-tablet/>

Jorveza[®] (budesonide) is indicated for the treatment of eosinophilic oesophagitis (EoE) in adults (older than 18 years of age)

Adverse events should be reported. Reporting forms and information can be found at www.yellowcard.mhra.gov.uk (UK residents) or www.hpra.ie (Irish residents). Adverse events should also be reported to Dr Falk Pharma UK Ltd at pv@dralfkpharma.co.uk.